10 al 14 de
noviembre
2024
Ciudad San Diego
(USA)

Sociedad Española de Reumatología

ACRreview 23

#ACReview23

AstraZeneca

ACRreview 23

#ACReview23

Sociedad Española de Reumatología

Espondiloartritis Clínica y Básica

Dra. Clementina López Medina

Servicio de Reumatología
Hospital Universitario Reina Sofía. Córdoba

AstraZeneca

0842 (O). Low rate of switching from nr-axSpA to r-axSpA after 10 years of follow-up in early axial spondyloarthritis. Data from DESIR cohort. Molto A, et al.

nr-axSpA → r-axSpA

Baseline → 10-years follow-up

"Completers" (n=299)

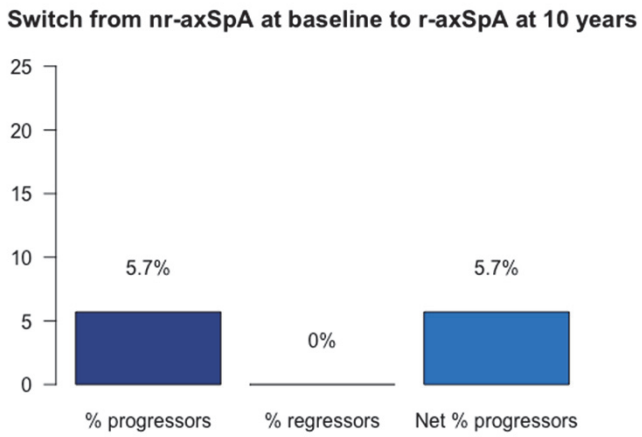

"Intention-to-follow" population (n=704)

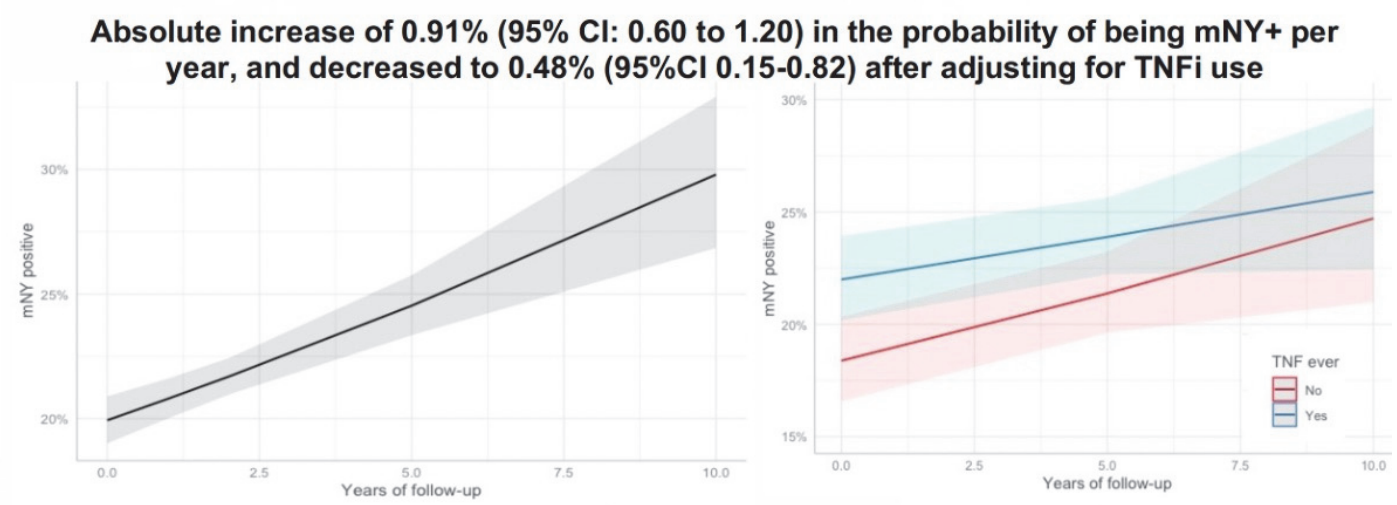

0842 (O). Low rate of switching from nr-axSpA to r-axSpA after 10 years of follow-up in early axial spondyloarthritis. Data from DESIR cohort. Molto A, et al.

Baseline factors associated with radiographic progression over the 10 years follow-up

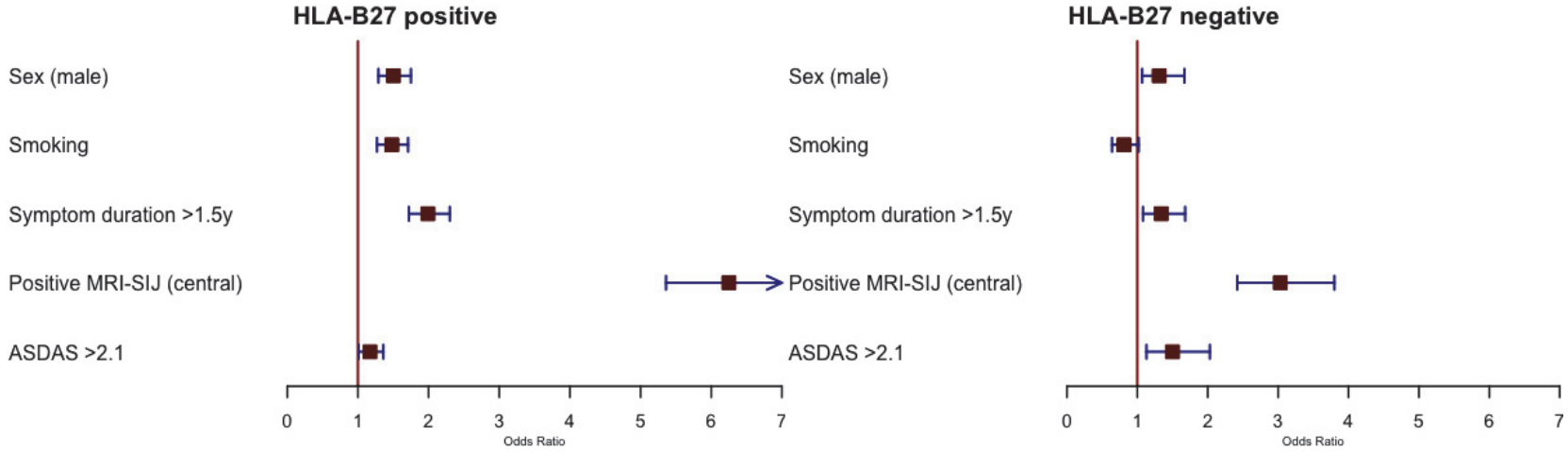

Conclusion:

- Patients with early axSpA have a low likelihood of changing from nr-axSpA to r-axSpA over 10 years, especially when considering the use of anti-TNF.
- Local inflammation on MRI-SIJ is strongly associated damage accrual in the SIJ over time, in particular in patients who are HLA-B27 positive.

0513 (P). Impact of pregancy on sacroiliac imaging in women with axial spondyloarthritis: results of the analysis of the DESIR cohort. Portier E, et al.

Imaging criteria *Mean (sd) or number (%)*	Nulliparous (N = 142)	Non-nulliparous (N = 232)	P-value*
X-ray criteria			
X-ray sacroiliitis	24 (16.9%)	23 (9.9%)	**p = 0.046**
New York score on right sacroiliac joint	0.72 (1.1)	0.61 (0.95)	NS
New York score on left sacroiliac joint	0.59 (1.02)	0.56 (0.96)	NS
Any erosion in the sacroiliac joints	28 (19.7%)	27 (11.6%)	**p = 0.031**
Any joint widening in the sacroiliac joints	0	2 (0.9%)	NS
Any sclerosis in the sacroiliac joints	27 (19%)	29 (12.5%)	NS
Any partial or total ankylosis in the sacroiliac joints	3 (2.1%)	3 (1.3%)	NS
MRI criteria			
Sacroiliitis on MRI	48 (33.8%)	45 (19.4%)	**p = 0.0016**
SPARCC score	3.6 (6.74)	2.42 (5.12)	NS
≥ 3 fatty lesions on MRI	12 (8.45%)	7 (3.02%)	**p = 0.013**
≥ 3 erosions on MRI	4 (2.82%)	4 (1.72%)	NS
≥ 5 fatty lesions and/or erosions on MRI	11 (7.75%)	5 (2.16%)	**p = 0.0086**
Number of any lesions on sacroiliac joint (0 to 144)	1.65 (3.51)	1.95 (4.55)	NS
Number of enthesitis (0 to 12)	0 (0)	0 (0)	NA
Number of erosions (0 to 40)	0.8 (1.53)	0.71 (1.57)	NS
Number of fatty lesions (0 to 40)	0.96 (9.52)	0.51 (1.74)	NS
Number of sclerosis (0 to 40)	0.125 (0.59)	0.38 (1.26)	**p = 0.03**
Number of partial or total ankylosis (0 to 24)	0.07 (0.64)	0.06 (0.53)	NS

Imaging criteria *Mean (sd) or number (%)*	Before pregnancy (N = 38)	After delivery (N = 38)	P-value
Radiographic criteria			
X-ray sacroiliitis	8 (21.1%)	9 (23.7 %)	p = 0.37
New York score on right sacroiliac joint	0.66 (1.06)	0.67 (0.86)	p = 1
New York score on left sacroiliac joint	0.67 (1.07)	0.95 (0.95)	**p = 0.037**
Any erosion in the sacroiliac joints	9 (23.7%)	9 (23.7%)	p = 0.48
Any joint widening in the sacroiliac joints	0	3 (7.9%)	NA
Any sclerosis in the sacroiliac joints	6 (15.8%)	9 (23.7%)	p = 0.13
Any partial or total ankylosis in the sacroiliac joints	1 (2.6%)	2 (5.3%)	p = 0.48
MRI criteria			
Sacroiliitis on MRI	18 (47.3%)	2 (5.2%)	p = 0.074
SPARCC score	3.94 (7.63)	0.39 (0.74)	p = 0.15
≥ 3 fatty lesions on MRI	4 (10.5%)	1 (2.6%)	p = 1
≥ 3 erosions on MRI	1 (2.6%)	0	NA
≥ 5 fatty lesions and/or erosions on MRI	1 (2.6%)	1 (2.6%)	p = 1
Number of any lesions on sacroiliac joint (0 to 144)	1.81 (3.36)	1.8 (2.92)	p = 0.1
Number of enthesitis (0 to 12)	0 (0)	0 (0)	NA
Number of erosions (0 to 40)	0.84 (2.36)	0.42 (0.7)	p = 1
Number of fatty lesions (0 to 40)	0.97 (2.01)	1 (2.02)	p = 0.15
Number of sclerosis (0 to 40)	0 (0)	0.26 (0.86)	p = 0.29
Number of partial or total ankylosis (0 to 24)	0 (0)	0 (0)	NA

Conclusion:

- Pregnancy does not seem to aggravate imaging of axSpA women when comparing imaging according to the antecedent of pregnancy. Following axSpA patients who had first pregnancy showed mild increase of left sacroiliitis score on X-ray after delivery, but not enough to be considered as “worsening”.

0844 (O). Facet joint inflammation is rare, but when present it is associated with facet joint ankylosis in radiographic axial spondyloarthritis patients from the SIAS cohort. De Hooge, et al.

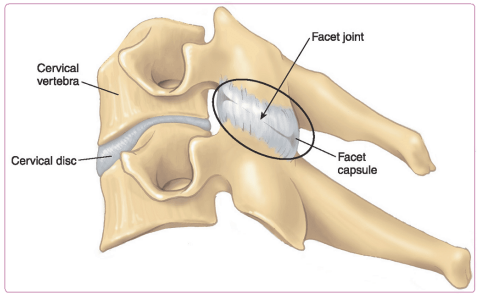

Inflammation in any part of the posterior elements			
PE inflammation	New facet joint ankylosis after one year	N*	P (FJ ankylosis/ PE inflammation)
0	0	7195	P (FJ ankylosis/0) = 43/7238 = 0.0059
0	1	43	
1	0	511	P (FJ ankylosis/1) =2/511 = 0.0039
1	1	2	
Inflammation only in the facet joint			
Facet joint inflammation	New facet joint ankylosis after one year	N#	P (FJ ankylosis/ FJ inflammation)
0	0	5934	P (FJ ankylosis/0) = 38/5972 = 0.0064
0	1	38	
1	0	93	P (FJ ankylosis/1) =1/94 = 0.0106
1	1	1	

OR 1.15 (95%CI 0.55 – 2.42)

OR 3.79 (95%CI 1.47 – 9.75)

Conclusion:

- PE inflammation and facet joint ankylosis on MRI were uncommonly present in r-axSpA patients.
- When inflammation in the FJ is present the likelihood of developing facet joint ankylosis after 1 year is over 3 times higher compared to FJ without inflammation.
- This finding adds to the pathophysiological relationship between inflammation and damage at the same anatomical location.

0846 (O). Preosteoclast plays a pathogenic role in syndesmophyte formation of ankylosing spondylitis through the secreted PDGFB-GRB2/ERK/RUNX2 Pathway. Tang Y, et al.

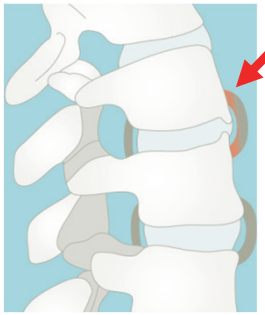

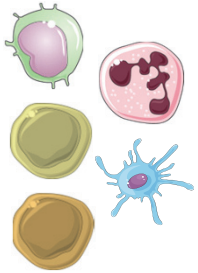

A

140 HC vs 140 AS

E

PDGFB and mSASSS

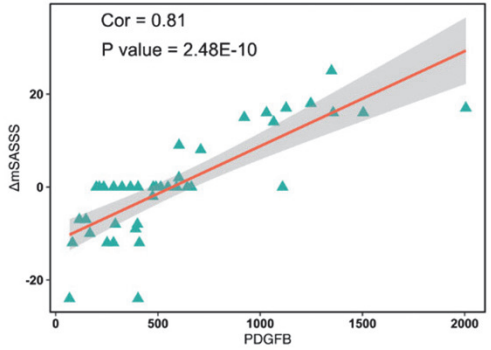

F

PDGFB in preosteoclasts

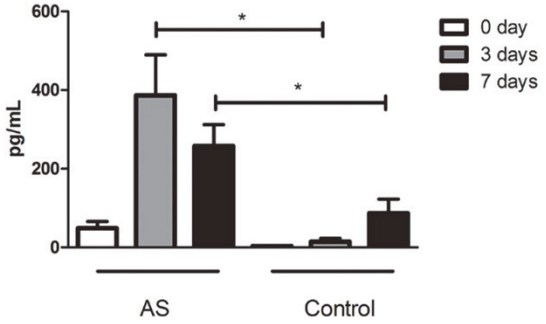

0846 (O). Preosteoclast plays a pathogenic role in syndesmophyte formation of ankylosing spondylitis through the secreted PDGFB-GRB2/ERK/RUNX2 Pathway. Tang Y, et al.

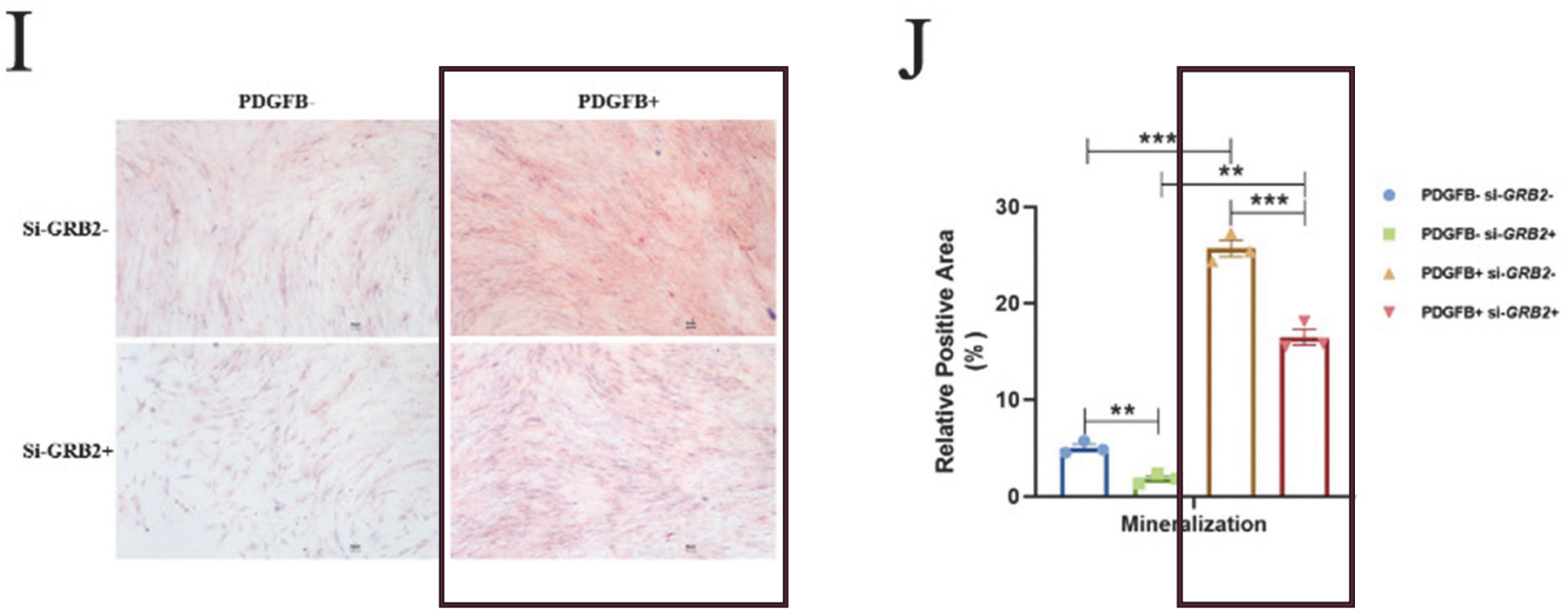

PDGFB promoted the proliferation, chemotaxis and migration of adipose-derived stem cells, promoting **osteoblastogenesis**

- **Conclusion:**
- PDGFB promotes osteoblastogenesis of ADSCs, which may contribute to pathological bone formation in AS.

10 al 14 de
noviembre
2024
Ciudad San Diego
(USA)

Sociedad Española de Reumatología

ACRreview 23

#ACReview23

AstraZeneca